

DOI: 10.21767/2254-6081.1000115

Neuroradiological Images of Five Selected Intracranial Tumors Encountered in our Practice

Uduma Felix U¹, Agwuna Kennedy K², Emejulu Jude KC³, Sylva Akpan⁴, Itanyi Ukamaka⁵, Motah Mathieu⁶ and Eke Bertha C⁷

¹Department of Radiology, Faculty of Clinical Sciences, College of Health Sciences, University of Uyo, Uyo, Nigeria

²Department of Radiation Medicine, University of Nigeria Teaching Hospital, Enugu, Nigeria

³Neurosurgical Unit, Department of Surgery, Nnamdi Azikiwe University Teaching Hospital, Nnewi, Nigeria

⁴Department of Ophthalmology, Faculty of Clinical Sciences, College of Health Sciences, University of Uyo, Uyo, Nigeria

⁵Department of Radiology, University of Abuja Teaching Hospital, Abuja, Nigeria

⁶Neurosurgical Unit, Department of Surgery, University of Douala, Douala, Cameroon

⁷Neurology Unit, Department of Internal Medicine, Faculty of Clinical Sciences, College of Health Sciences, University of Uyo, Uyo, Nigeria

Corresponding author: Uduma Felix U, Department of Radiology, Faculty of Clinical Sciences, College of Health Sciences, University of Uyo, Uyo, Nigeria, Tel: 2348146129875; E-mail: felixuduma@yahoo.com

Received: 09 November 2016; **Accepted:** 14 November 2016; **Published:** 18 November 2016

Citation: Uduma Felix U, Agwuna Kennedy K, Emejulu Jude KC, et al. Neuroradiological Images of Five Selected Intracranial Tumors Encountered in our Practice. Arch Can Res. 2016, 4: 4.

Abstract

Aim: Emphasizing some neuroradiological pictorial diagnostic features of certain intracranial tumors.

Introduction: There are diverse intracranial tumors and many of them are known to have some salient diagnostic features in neuro imaging.

Keywords: Chordoma; Medulloblastoma; Acoustic neuroma; Meningioma; Gliomablastoma multiforme; MRI; CT

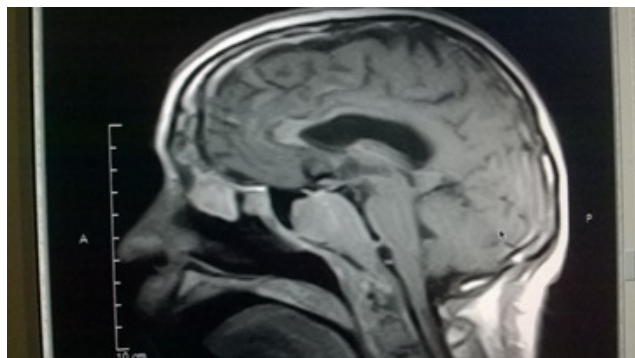


Figure 1A Brain T1W sagittal MR image shows the clivus has been replaced by an isointense soft tissue mass (Chordoma) in a 60-year-old woman.

Image Presentations

Case A

Brain MRI of a 60-year-old woman who presented with headache and tongue weakness showed that the clivus has been replaced by a T1W isointense and T2W hyperintense soft tissue mass with heterogenous enhancement. A diagnosis of chordoma was made (**Figures 1A-1C**).

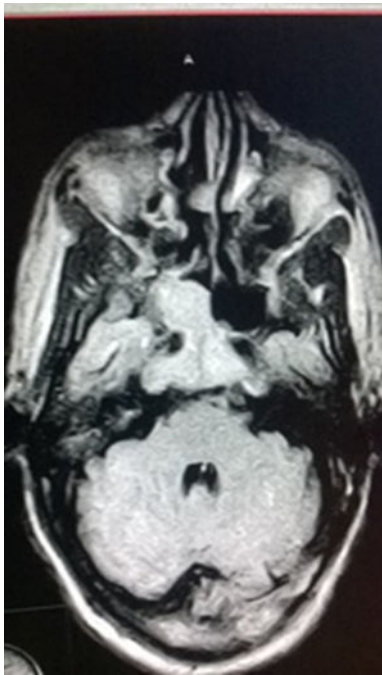


Figure 1B Axial FLAIR MR image showing the hyperintense bilobed mass posterior and compressing the right nasopharynx and anterior to the brainstem (Chordoma).

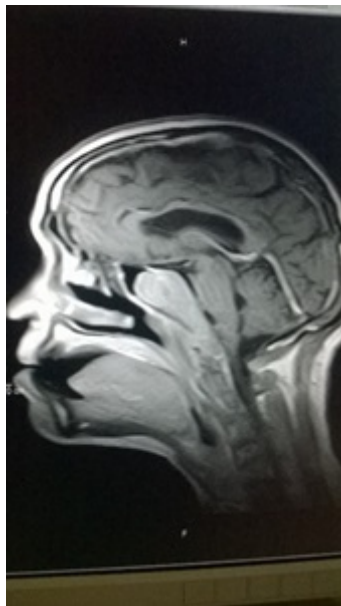


Figure 1C Gd-DPTH Contrast enhanced sagittal T1W MR image shows the homogeneously enhanced clival mass (chordoma).

necrotic centre. This mass compresses and displaces the fourth ventricle to the left. Only the solid component enhanced (Medulloblastoma) (**Figures 2A-2C**).

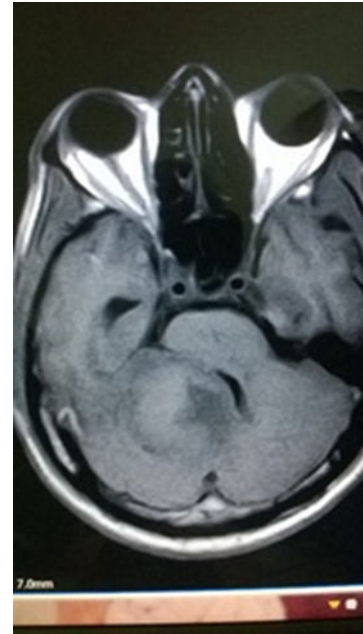


Figure 2A Brain axial T1W MR image of a 15-year-old male showing heterogenous solid mass in the right cerebellar peduncle with an area of hypointense necrotic centre. This mass compresses and displaces the fourth ventricle to the left (Medulloblastoma).

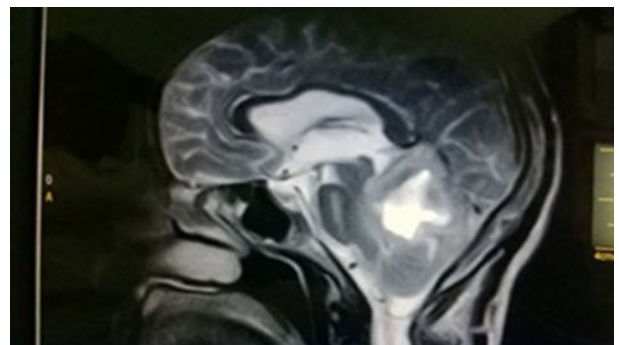

Figure 2B T2W sagittal MR image defines the mass as infratentorial and heterogeneously hyperintense (Medulloblastoma).

Case B

A 15-year-old male presented with headache and abnormal gait. Brain MRI showed T1W isointense solid infratentorial mass in the right cerebellar peduncle with a hypointense

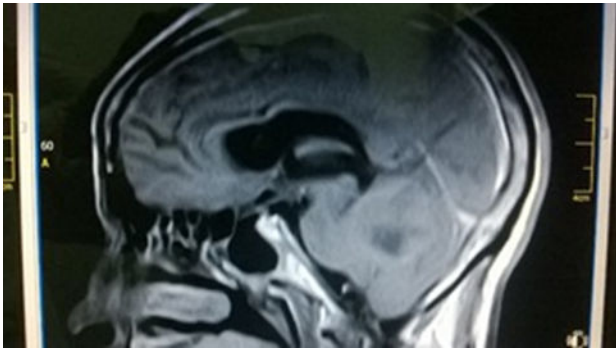


Figure 2C Sagittal T1W contrast enhanced image showing the above infratentorial mass to have enhanced solid component but unenhanced necrotic centre (Medulloblastoma).

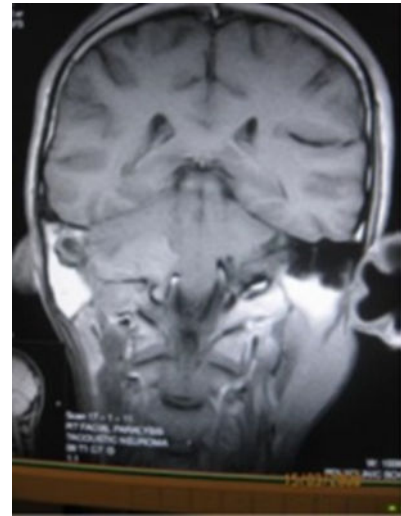


Figure 3B Brain coronal enhanced MR image showing homogenous enhancement of the right cerebellopontine angle.

Case C

A 51-year-old male presented with right unilateral sensorineural hearing loss and disequilibrium. Brain MRI showed extracanalicular right cerebellopontine angle soft tissue T1W isointense, T2W hyperintense and enhancing mass (Acoustic neuroma) (**Figures 3A and 3B**).

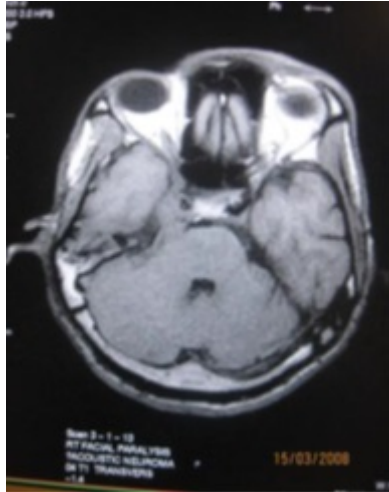


Figure 3A Brain axial T1W MR image of a 51-year-old male showing extracanalicular right cerebellopontine angle soft tissue isointense mass (Acoustic neuroma).

Case D

A 55-year-old female presented with persistent headache. Brain MRI showed a convexity T1W hypointense and T2W hyperintense frontal parafalcine soft tissue mass without surrounding oedema (Meningioma) (**Figures 4A and 4B**).

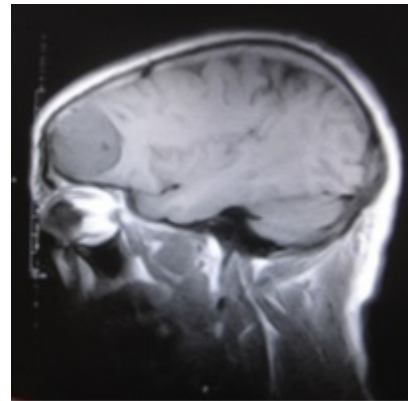


Figure 4A Sagittal T1W brain MR image of a 55-year-old female showing convexity hypointense lesion in the frontal region of the brain and abutting on the dura (Meningioma).

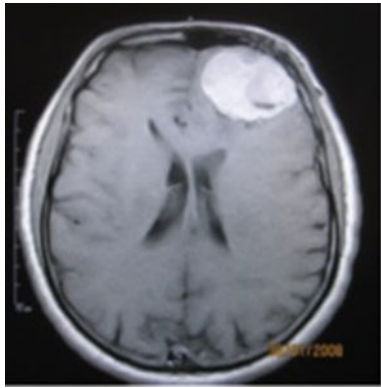


Figure 4B Axial contrast enhanced T1W MR image showing avidly enhancing left anterior parafalcine soft tissue mass without surrounding oedema but has dural tail (Meningioma).

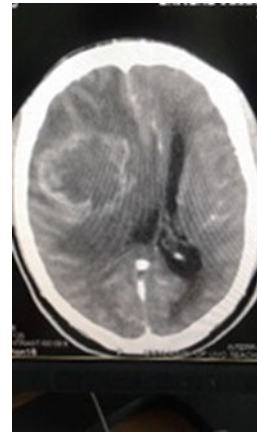


Figure 5B Enhanced axial brain CT of this 52-year-old male shows a ring enhancing lesion in the right fronto-parietal cerebral lobes with surrounding hypodense cytotoxic oedema.

Case E

A 52-year-old male presented with occasional loss of consciousness and severe headache. Brain CT showed extensive right cerebral edema with effacement of ipsilateral lateral ventricle. Enhanced CT image revealed a ring enhancing lesion in the right fronto-parietal cerebral lobes with surrounding hypodense cytotoxic oedema. (Glioma multiforme) (**Figures 5A and 5B**).

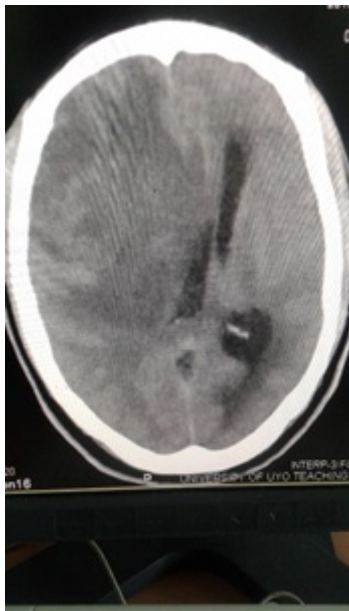

Figure 5A A 52-year-old male with brain axial CT showing extensive right cerebral hypodense edema with effacement of ipsilateral ventricle.

Conclusion

We have carefully chosen five intracranial tumours of diverse locations to highlight the import of neuroimaging in diagnosis. These tumours are intracranial chordoma (a parasellar tumour), medulloblastoma (infratentorial tumour), acoustic neuroma (cerebello-pontine angle tumour), meningioma (a predominantly convexity tumour) and glioblastoma multiforme (supratentorial tumour). Since this is a pictorial representation, we will only take a cursory look at the neuroimaging features of these tumours.